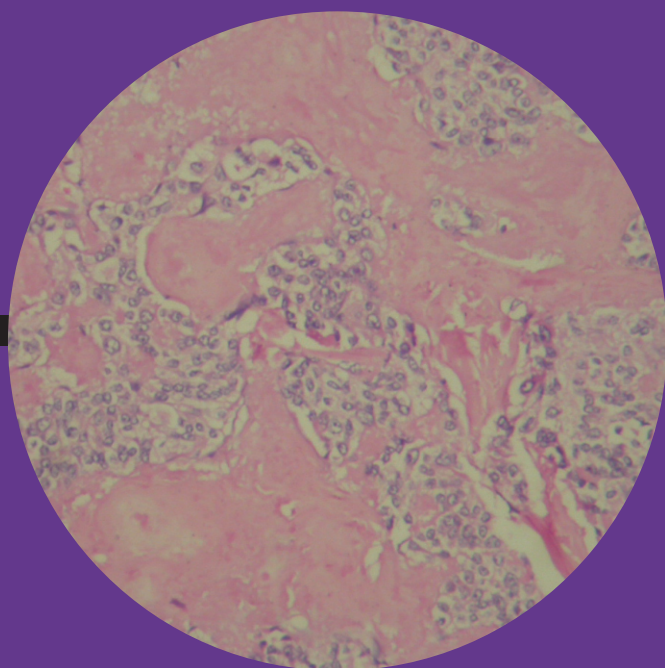


2011 / Vol 15 / Supplement 2 (Thyroid)

Indian Journal of Endocrinology and Metabolism

Official Publication of The Endocrine Society of India

www.ijem.in



GUEST EDITOR: RAKESH SAHAY

Elevated thyroid stimulating hormone in a neonate: Drug induced or disease?

Sunil Kumar Kota, Kirtikumar Modi, Karuppiah Kumaresan¹

Department of Endocrinology, Medwin Hospital, Hyderabad, ¹Department of Nuclear Radiology, K. K. Nuclear Scans, Hyderabad, India

ABSTRACT

Dyshormonogenesis is an uncommon cause of congenital hypothyroidism. The most common abnormality is absent or insufficient thyroid peroxidase enzyme. Maternal intake of antithyroid drug can also lead to elevated thyroid stimulating hormone (TSH) in a neonate, albeit the scenario is temporary. We report one such interesting case where a clinically euthyroid neonate borne to a mother on antithyroid drug presents on 12th day of life with reports of elevated TSH and increased tracer uptake in 99mTc thyroid scan. Disproportionately high TSH in comparison to low maternal antithyroid drug dosage and further elevation of TSH after stopping mother's antithyroid drugs ruled out maternal antithyroid drug-induced congenital hypothyroidism in the baby. Early institution of therapy in these patients can prevent mental retardation and other features of hypothyroidism.

Key words: Antithyroid drug, congenital hypothyroidism, dyshormonogenesis

INTRODUCTION

The worldwide incidence of congenital hypothyroidism (CH) is 1:3000 to 1:5000 live births.^[1] Dyshormonogenesis and maternal intake of antithyroid drugs are less common causes of CH. Inherited defects in hormone biosynthesis (dyshormonogenesis) are rare causes of CH and account for 10%-15% children with hypothyroidism.^[2] Dyshormonogenesis results from a deficiency or absence of one or more of the enzymes involved in the thyroid hormone synthesis or secretion. The most common enzyme abnormality is absent or insufficient thyroid peroxidase (TPO) activity which results in the failure of oxidation of iodide into iodine.^[3] With this type of defect, iodine will be trapped but not organified. Prevalence of maternal antithyroid drug-induced transient congenital

hypothyroidism is still less common at 1:11 000 to 1:15 000.^[4] We report one such interesting case of a neonate, born to a hyperthyroid mother, presenting with markedly elevated thyroid stimulating hormone (TSH), causing initial confusion regarding the etiology.

CASE REPORT

A newborn child, product of a consanguineous marriage, was brought by his parents on the 12th day for evaluation. The Baby was delivered at term by cesarean section with uneventful birth history. Mother is hyperthyroid receiving carbimazole 15 mg/day in last 3 months of gestation that was subsequently changed over to propylthiouracil 50 mg twice daily after delivery, by the gynecologist prior to her consultation with us. We considered sticking to the medication in view of normal TSH and T₄ in the mother. A Maternal cousin and 3 maternal aunts of the mother have primary hypothyroidism. On examination, baby had weight of 2.7 kg and length 50 cm. Clinically, the baby appeared euthyroid without any stigma of CH such as macroglossia, umbilical hernia, or hypothermia. There was no palpable goiter. Rest of the systemic examination was normal. Thyroid profile of the baby, done on 11th day after delivery, revealed T₃-163.3 ng/dl (N-75-260 ng/dl), T₄-10.1

Access this article online

Quick Response Code:



Website:
www.ijem.in

DOI:
10.4103/2230-8210.83355

Corresponding Author: Dr. Sunil Kumar Kota, Department of Endocrinology, Medwin Hospitals, Chiragh Ali Lane, Nampally, Hyderabad 500 001, Andhra Pradesh, India. E-mail: hidocsunil@ibibo.com

µg/dl (N-6.1--14.9), and TSH-78.4 µIU/ml (N-0.7--15.4). Baby was subjected to radioisotope ^{99m}Tc thyroid scan, which enlarged thyroid gland in normal pretracheal location and increased avid tracer uptake [Figure 1]. For further clarification, the mother was advised to stop propylthiuracil for 4 days, and then to repeat thyroid function test for the baby. On recall, the baby's repeated thyroid profile revealed T_3 -167.15 ng/dl, T_4 -6.6 µg/dl, and TSH-131.56 µIU/ml. For elevated TSH with increased radioactive tracer uptake on thyroid scan, probability of maternal drug induced hypothyroidism or dysmorphogenesis were considered. Disproportionately high levels of baby's TSH in comparison to small dosage of antithyroid drugs (propylthiuracil 100 mg/day) consumed by the mother and further elevation of TSH in spite of stopping mother's antithyroid drugs made the possibility of antithyroid drug induced congenital hypothyroidism less likely. Considering dysmorphogenesis as a cause of baby's elevated TSH, the baby was prescribed 25 µg levothyroxine daily. Repeat TSH after 2 weeks of therapy was 11.5 µIU/ml and T_4 was 11.9 µg/dl. Baby was advised for follow up after 1 month with T_4 and TSH.

DISCUSSION

Dysgenesis (Athyrosis, hypoplasia, ectopy) of thyroid gland is the most common cause of congenital hypothyroidism (80% cases).^[3] These can easily be diagnosed by elevated TSH and absent/ectopic tracer uptake on radioisotope thyroid scan. However, when elevated TSH is associated with increased tracer uptake on radioisotope scan, possible causes include iodine deficiency, dysmorphogenesis, and maternal antithyroid drug intake. Our patient had a similar situation.

Iodine deficiency related such high level of TSH (78.4 µIU/ml), would usually be associated with clinically overt

hypothyroidism, a palpable goiter in most cases and low T_3 and T_4 . Our patient had none of these features.^[5]

Transplacental transfer of maternal TSH-R antibody results in a transient form of central hypothyroidism, where because of inactivity of TSH at TSH receptors, the glandular radio isotope uptake is low to undetectable. TSH-R antibody induced thyrotoxicosis in the baby can be ruled out because of low T_4 accompanied by normalization of high TSH after thyroxine replacement therapy.

Maternal antithyroid drug can cause elevated TSH in neonate. Transplacental transfer of maternal antithyroid drugs can block thyroid peroxidase step in the baby, but there is intact iodide uptake giving rise to increased tracer uptake in radioisotope scan due to stimulatory effect of high TSH.^[6] However, dosage of maternal antithyroid drug is usually quite high unlike our case (100 mg PTU). Rising levels of TSH in spite of stopping antithyroid drug for mother made this possible etiology less likely.

Based on this, dysmorphogenesis was considered as possible diagnosis to explain high levels of TSH and increased tracer uptake in ^{99m}Tc scan. Dysmorphogenesis is an uncommon cause of goitrous hypothyroidism and account for only about 10%--15% of cases of CH.^[2] In most instances, the defect appears to be transmitted as an autosomal recessive trait, more so in consanguineous families. The clinical manifestations of CH due to biochemical defect are similar to those in infants with thyroid dysgenesis, but less severe, depending on the degree of dysmorphogenesis. In our case, there was no clinical evidence of CH, owing to milder degree of dysmorphogenesis reflected by normal total T_3 and T_4 . Because of trophic actions of high TSH, thyroid gland enlarges. Our case had enlarged thyroid on scintigraphy, though clinically goiter was not palpable. In general, the more severe the biosynthetic defect, the earlier the goiter appears, the larger it is, and the greater the likelihood of early development of hypothyroidism or even cretinism. In patients with iodination/organification defects, only part or none of the iodide taken up is oxidized and organified. In these cases T_4 production is decreased, whereas the synthesis of Tg and transport of iodide are strongly stimulated by TSH. Radioiodine uptake is high owing to intact NaI (Sodium Iodide) symporter stimulated by high TSH, and the block in iodide oxidation and organification results in an increase in intracellular iodide concentration. This can be measured by determining the amount of radioiodine lost from the gland after the administration of potassium perchlorate (perchlorate discharge test); the percentage released indicates whether a defect is partial or total.^[7] Total iodide organification defects are characterized by discharge of more than 50% of the

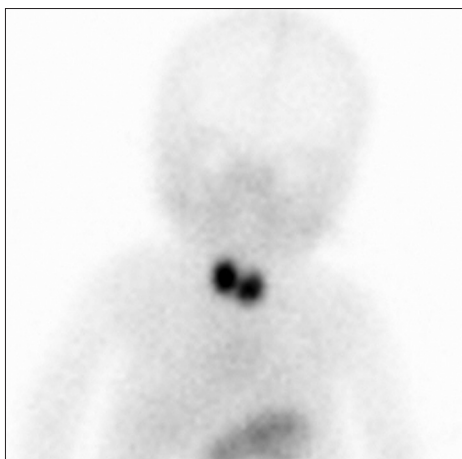

Figure 1: ^{99m}Tc thyroid scan- enlarged thyroid gland with increased avid tracer uptake

radioiodine in the thyroid gland within two hours after administration of potassium perchlorate. Partial defects are characterized by discharge of more than 10% of the accumulated radioiodine.^[8] In such patients a ^{99m}Tc thyroid scan shows increased uptake and can mimic thyrotoxicosis.^[9] Upon thyroid I¹³¹ scan, initial uptake will be normal, owing to normal iodine uptake. But the delayed uptake would be abnormal, owing to defective iodination/ organification. Our patient showed increased uptake of ^{99m}Tc on thyroid scan.

The baby was prescribed 25 µg of thyroxine. Treatment in a case of congenital hypothyroidism should be started at the earliest within the first 2 weeks.^[10] The thyroxine replacement dosages as per different age groups are 0-3 months: 10-15 µg/kg, 3-6 months: 8-10 µg/kg, 6-12 months: 6-8 µg/kg, 1-5 years: 5-6 µg/kg, 6-12 years: 4-5 µg/kg, and >12 years: 2-3 µg/kg.^[11] Follow up is to be done at every 2-4 weeks for initial 3 months, every 1-2 months up to 1 year, every 2-3 months from 1 to 3 years, and then every 3-6 months till growth is completed. If dosage is changed, next follow up visit is to be done within 2-4 weeks. Serum T4 has to be maintained in upper half of normal range in the first 3 years. Bone age is measured before onset of treatment and yearly once then onwards with a goal of attaining normal bone maturation by 3 years. Growth monitoring is to be done in every 3 months.

REFERENCES

1. Klett M. Epidemiology of congenital hypothyroidism. *Exp Clin Endocrinol Diabetes* 1997; 105:19-23.
2. Desai MP. Disorders of thyroid gland in India. *Indian J Paediatr* 1997;64:11-20.
3. Shankar SM, Menon PS, Karmarkar MG, Gopinath PG. Dysgenesis of thyroid in the common type of childhood hypothyroidism in environmentally iodine deficient areas of north India. *Acta Paediatr* 1994;83:1047-51.
4. Kempers MJ, van Tijn DA, van Trotsenburg AS, de Vijlder JJ, Wiedijk BM, Vulsma T. Central congenital hypothyroidism due to gestational hyperthyroidism: Detection where prevention failed. *J Clin Endocrinol Metab* 2003;88:5851-7.
5. Spitzweg C, Morris JC. The sodium iodide symporter: Its pathophysiological and therapeutic implications. *Clin Endocrinol (Oxf)* 2002;57:559-74.
6. Fisher D. Next generation newborn screening for congenital hypothyroidism? *J Clin Endocrinol Metab* 2005;90:3797-9.
7. Baschieri L, Benedetti G, Deluca F, Negri M. Evaluation and limitations of the perchlorate test in the study of thyroid function. *J Clin Endocrinol Metab* 1963;23:786-91.
8. McDougall IR. *In vivo* radionuclide tests and imaging. In: Braverman LE, Utiger RD. *Werner and Ingbar's The Thyroid*. 9th ed. Lippincott Williams & Wilkins; 2005. p 309-28.
9. Sfakianakis GN, Ezuddin SH, Sanchez JE, Eidson M, Cleveland W. Pertechnetate scintigraphy in primary congenital hypothyroidism. *J Nucl Med* 1999;40:799-804.
10. Dubuis JM, Glorieux J, Richer F, Deal CL, Dussault JH, Van Vliet G. Outcome of severe congenital hypothyroidism: Closing the developmental gap with early high dose levothyroxine treatment. *J Clin Endocrinol Metab* 1996;81:222-7.
11. Selva KA, Mandel SH, Rien L, Sesser D, Miyahira R, Skeels M, *et al.* Initial treatment dose of L-thyroxine in congenital hypothyroidism. *J Pediatr* 2002;141:786-92.

Cite this article as: Kota SK, Modi K, Kumaresan K. Elevated thyroid stimulating hormone in a neonate: Drug induced or disease?. *Indian J Endocr Metab* 2011;15:S138-40.

Source of Support: Nil, **Conflict of Interest:** None declared.